

Percutaneous closure of a postoperative residual atrial septal defect with the Occlutech Figulla Occluder device

Ameliyat sonrası rezidüel atriyal septal defektin perkütan yolla Occlutech Figulla tıkaçıcı cihaz ile kapatılması

Bülent Demir, M.D., Hande Oktay Türeli, M.D., Gönül Kutlu, M.D., Osman Karakaya, M.D.

Department of Cardiology, Bakırköy Sadi Konuk Education and Research Hospital, İstanbul

Summary – A 67-year-old male patient with an eight-month history of operation for mitral valve repair and secundum atrial septal defect (ASD) presented with complaints of fatigue and shortness of breath. Transthoracic echocardiography showed a residual ASD resulting from separation of a pericardial patch. Qp/Qs rate was 3.2. The diameter of the residual defect measured by transesophageal echocardiography was 18 mm. During right heart catheterization, pulmonary artery pressure was estimated to be 50 mmHg. Using the percutaneous method accompanied by transesophageal echocardiography guidance, the residual defect was successfully closed with a 21-mm Occlutech Figulla device. Postprocedural echocardiographic control showed no leaks. The patient was discharged with 300 mg/day aspirin treatment.

Özet – Sekiz ay önce mitral kapak tamiri ve sekundum atriyal septal defekti kapatma nedeniyle ameliyat edilen 67 yaşında erkek hasta yorgunluk ve nefes darlığı yakınmalarıyla başvurdu. Transtorasik ekokardiyografi incelemesinde perikardiyal yamanın yerinden ayrılması sonucu rezidüel atriyal septal defekt saptandı. Qp/Qs oranı 3.2 olarak hesaplandı. Transözofageal ekokardiyografide rezidüel defektin çapı 18 mm ölçüldü. Sağ kalp kateterizasyonu ile pulmoner arter basıncı 50 mmHg bulundu. Defekt, devamlı transözofageal ekokardiyografi eşliğinde perkütan yöntemle, 21 mm'lik Occlutech Figulla tıkaçıcı cihazı kullanılarak başarılı şekilde kapatıldı. İşlem sonrası ekokardiyografik kontrolde kaçak izlenmedi. Hasta 300 mgr/gün aspirin tedavisi ile taburcu edildi.

Secundum type atrial septal defect is a prevalent congenital heart disease among adult

Abbreviations:

ASD Atrial septal defect
TEE Transesophageal echocardiography
TTE Transthoracic echocardiography

patients. Open heart surgery has been commonly used since 1950 for ASDs. However, there are some disadvantages associated with open heart surgery.^[1] Today, percutaneous transcatheter closure has become more common, replacing surgical repair for suitable patients.^[2] It has also been demonstrated that percutaneous transcatheter closure may reliably be performed for postoperative residual ASD treatment with high success rates, even though there are limited number of cases.^[3]

We present a case of residual ASD that was successfully closed with the Occlutech Figulla ASD Occluder following separation of a surgical patch.

CASE REPORT

A 67-year-old male patient presented to our hospital with fatigue and shortness of breath, eight months after a previous operation for a secundum ASD and for mitral valve repair with mitral ring annuloplasty. Physical examination showed fixed splitting of S₂ and a 2/6 systolic murmur at the upper left portion of the sternum. Electrocardiography showed sinus arrhythmia and right bundle branch block. Transthoracic echocardiography and color Doppler demon-

Received: July 21, 2011 Accepted: November 2, 2011

Correspondence: Dr. Bülent Demir. Ataköy 9. Kısım, B-28 Blok, 12. Kat, D: 50, 34156 Bakırköy, İstanbul, Turkey.
Tel: +90 212 - 414 71 86 e-mail: drbdmr06@hotmail.com

© 2012 Turkish Society of Cardiology

strated a right-to-left shunt due to patch detachment. The defect diameter was measured as 18 mm by TTE. Transesophageal echocardiography was performed to pinpoint the defect site, measure the defect diameter, and determine the rim lengths, where mid-esophageal views depicted patch detachment. Color Doppler demonstrated a right-to-left shunt (Fig. 1a, b). Mid-

esophageal 4-chamber, short-axis, and bicaval views demonstrated a defect 18 mm in diameter. Anterior, posterior, inferior, and superior rims were longer than 5 mm each. Moderate central mitral failure and moderate tricuspid failure were observed. All pulmonary veins appeared normal. There was no thrombus formation in the cardiac chambers and left atrial append-

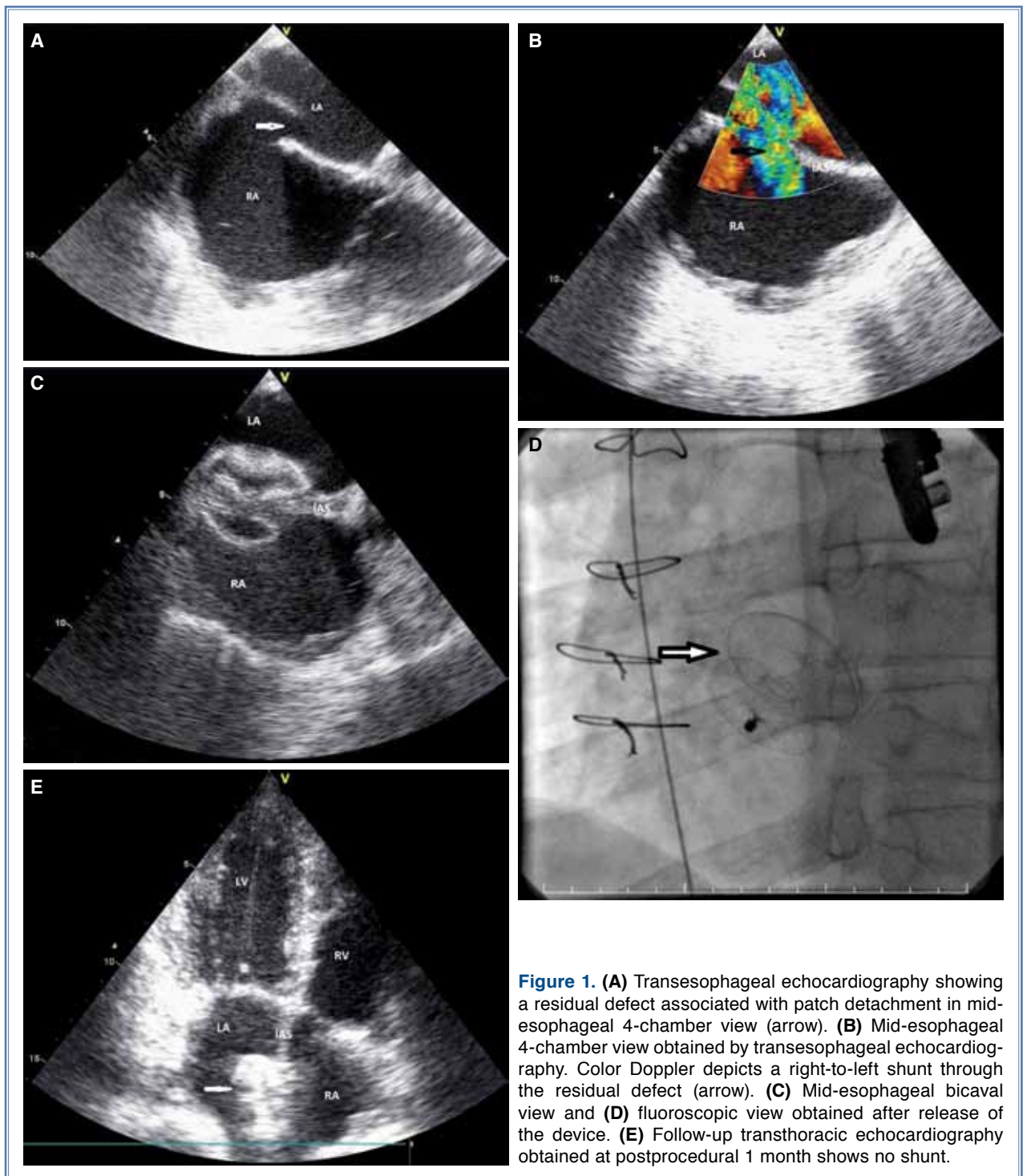


Figure 1. (A) Transesophageal echocardiography showing a residual defect associated with patch detachment in mid-esophageal 4-chamber view (arrow). (B) Mid-esophageal 4-chamber view obtained by transesophageal echocardiography. Color Doppler depicts a right-to-left shunt through the residual defect (arrow). (C) Mid-esophageal bicaval view and (D) fluoroscopic view obtained after release of the device. (E) Follow-up transthoracic echocardiography obtained at postprocedural 1 month shows no shunt.

age. Percutaneous transcatheter closure was planned for the residual ASD. The patient was transferred to the catheterization laboratory for the hemodynamic workup and percutaneous procedure. With right heart catheterization, systolic pulmonary artery pressure was measured as 50 mmHg, diastolic pulmonary artery pressure as 27 mmHg, mean pulmonary artery pressure as 35 mmHg, and Qp/Qs was 3.0. During the procedure, the patient received 2 mg midazolam and continuous TEE guidance. A 6-Fr multipurpose catheter and a 0.035 inch rigid guide wire were inserted into the femoral vein, advanced across the defect, and the rigid guide wire was placed into the left upper pulmonary vein. After extending the carrier system through the rigid guide wire up to the opening of the pulmonary vein without applying balloon sizing, a 21-mm Occlutech Figulla Occluder device (Occlutech GmbH, Jena, Germany), which was 3 mm larger than the defect diameter measured by TEE, was withdrawn slightly by initially opening the right atrial disc. After ensuring that it was positioned at 30° in short-axis aortic view next to the septum under TEE, the right atrial disc was opened and the device was placed. Device stability was controlled by the Minnesota maneuver and the device was released. Follow-up TEE and fluoroscopy demonstrated complete closure of the defect with no compression over the adjacent important structures and heart valves (Fig. 1c, d). The procedure was ended without any complications. Trans-thoracic echocardiography applied on the following day showed that the device preserved its location, and no shunt was seen by color Doppler. The patient was discharged with 300 mg/day aspirin. Follow-up TTE at postprocedural 1 month demonstrated complete closure of the defect and color Doppler demonstrated no signs of shunt. The right atrium and ventricle exhibited a significant reduction in size and the estimated systolic pulmonary artery pressure calculated from the tricuspid insufficiency was measured as 30 mmHg (Fig. 1e).

DISCUSSION

Atrial septal defect is the most common congenital heart disease in adults and comprises about 5-10% of all cardiac diseases.^[4] Although it is generally asymptomatic during early periods, it induces volume overload in the right ventricle and right atrium with advancing age, and can cause pulmonary hypertension and right ventricular insufficiency as well as Eisenmenger syndrome at elderly ages. Moreover, ASD patients may develop complications such as arrhythmias

and paradoxical embolism. Therefore, it should be closed upon diagnosis both in children and adults unless there is an evident contraindication.

Recent developments in interventional cardiology apply to congenital heart diseases, as well. Although surgical closure, the traditional method in ASD treatment, has lower morbidity and mortality rates compared with coronary artery bridging, it still has disadvantages such as requirement of sternotomy/thoracotomy, and complications including postoperative pain, infection, and permanent scar formation.^[5] Moreover, 7-8% of patients develop residual shunts during long-term postoperative follow-up.^[6] Therefore, transcatheter closure of ASDs is performed in many centers, as a replacement to surgical method due to its easy-to-apply character, low complication rate, and high success rate. In 85-90% of patients, the defect is successfully closed by transcatheter ASD closure without serious shunts.

The Amplatzer Septal Occluder is the most frequently employed device in transcatheter ASD closure procedures. The Occlutech Figulla Occluder is a newer device with a structure similar to that of the Amplatzer Septal Occluder. Paç et al.^[7] compared the two devices in percutaneous ASD closure and obtained similar outcomes with regard to clinical efficacy and safety.

We did not use the balloon-sizing technique which is recognized as the gold standard for estimation of defect diameter and device size. Two-dimensional TTE, TEE, and three-dimensional TEE have been shown to be effective and reliable methods for determination of the defect diameter without balloon sizing.^[8]

The number of studies focusing on the use of percutaneous method in the treatment of postoperative residual ASDs is limited. Chessa et al.^[3] used transcatheter closure in four of five cases with postoperative residual ASD. They used the CardioSEAL system in three cases, and the Amplatzer Septal Occluder in one case. In our country, a 17-year-old patient with postoperative residual ASD was successfully treated using the Amplatzer Septal Occluder.^[9] Based on a review of the related literature, ours represents the first residual ASD case treated by the Occlutech Figulla Occluder device.

In conclusion, percutaneous closure method can be preferred in both secundum ASD cases and postoperative residual ASD cases using the same technique and selection criteria. It offers several advantages such as long-term outcomes comparable to surgical treat-

ment, less invasive nature compared with surgery, reduced postprocedural complication rate, and cost-effectiveness.

Conflict-of-interest issues regarding the authorship or article: None declared

REFERENCES

1. Bialkowski J, Karwot B, Szkutnik M, Banaszak P, Kusa J, Skalski J. Closure of atrial septal defects in children: surgery versus Amplatzer device implantation. *Tex Heart Inst J* 2004;31:220-3.
2. Harper RW, Mottram PM, McGaw DJ. Closure of secundum atrial septal defects with the Amplatzer septal occluder device: techniques and problems. *Catheter Cardiovasc Interv* 2002;57:508-24.
3. Chessa M, Butera G, Giamberti A, Bini RM, Carminati M. Transcatheter closure of residual atrial septal defects after surgical closure. *J Interv Cardiol* 2002;15:187-9.
4. Therrien J, Webb GD. Congenital heart disease in adults. In: Braunwald E, Zipes DP, Libby P, editors. *Heart disease: a textbook of cardiovascular medicine*. 6th ed. Philadelphia: W. B. Saunders; 2001. p. 1592-621.
5. Du ZD, Hijazi ZM, Kleinman CS, Silverman NH, Larntz K; Amplatzer Investigators. Comparison between transcatheter and surgical closure of secundum atrial septal defect in children and adults: results of a multicenter non-randomized trial. *J Am Coll Cardiol* 2002;39:1836-44.
6. Murphy JG, Gersh BJ, McGoon MD, Mair DD, Porter CJ, Ilstrup DM, et al. Long-term outcome after surgical repair of isolated atrial septal defect. Follow-up at 27 to 32 years. *N Engl J Med* 1990;323:1645-50.
7. Paç A, Polat TB, Çetin İ, Oflaz MB, Ballı S. Figulla ASD occluder versus Amplatzer Septal Occluder: a comparative study on validation of a novel device for percutaneous closure of atrial septal defects. *J Interv Cardiol* 2009;22:489-95.
8. Gupta SK, Sivasankaran S, Bijulal S, Tharakan JM, Harikrishnan S, Ajit K. Trans-catheter closure of atrial septal defect: balloon sizing or no balloon sizing - single centre experience. *Ann Pediatr Cardiol* 2011;4:28-33.
9. Karakurt C, Koçak G, Elkıran Ö. Transcatheter closure of postsurgical residual atrial septal defect with Amplatzer Septal Occluder: case report. *Türkiye Klinikleri J Cardiovasc Sci* 2011;23:75-8.

Key words: Coronary angiography; echocardiography; heart catheterization; heart septal defects, atrial/therapy; septal occluder device.

Anahtar sözcükler: Koroner anjiyografi; ekokardiyografi; kalp kate-terizasyonu; kalp septal defekti, atriyal/tedavi; septal tıkaçıcı cihaz.