

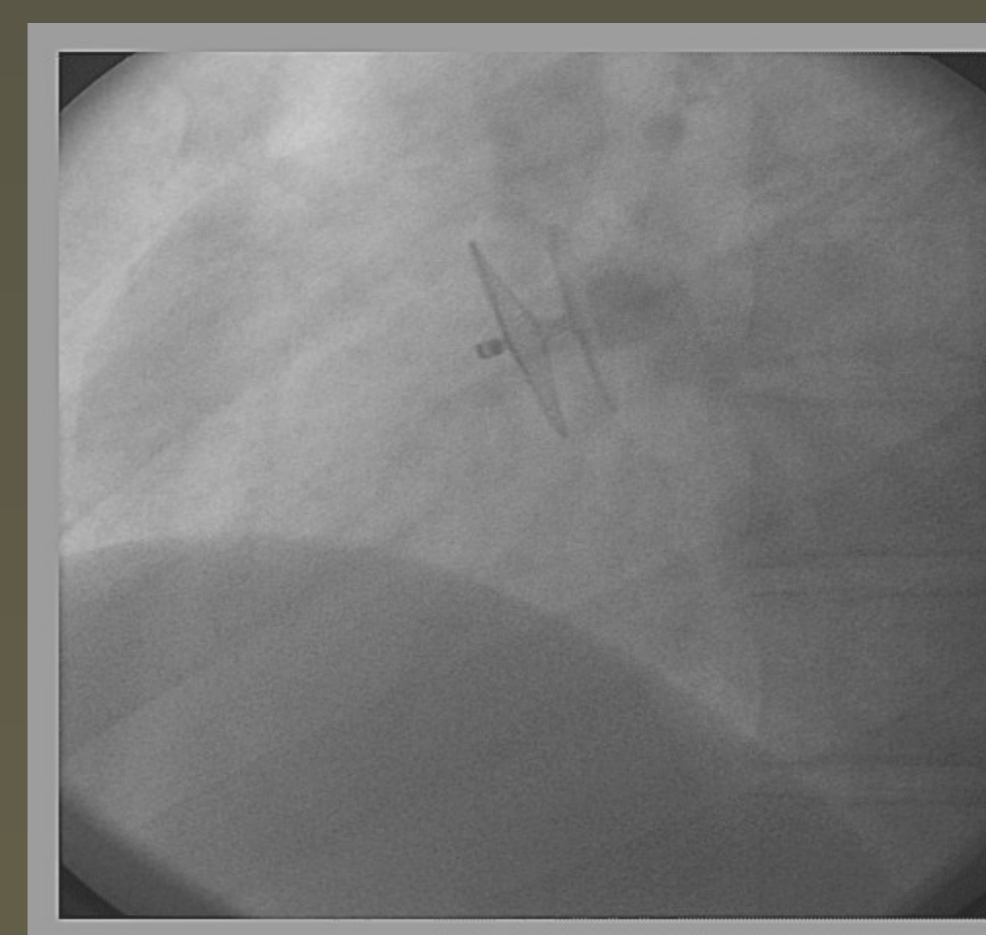
Three years of experience using Occlutech Figulla PFO occluder

EDMUNDO CLARINDO OLIVEIRA e MARCO ANTÔNIO MOURA,
Hospitals: Felício Rocho, Life Center, Vera Cruz; BH, MG - BRAZIL.

Introduction: Closure of PFO has been proved to be safe and effective using different types of devices.

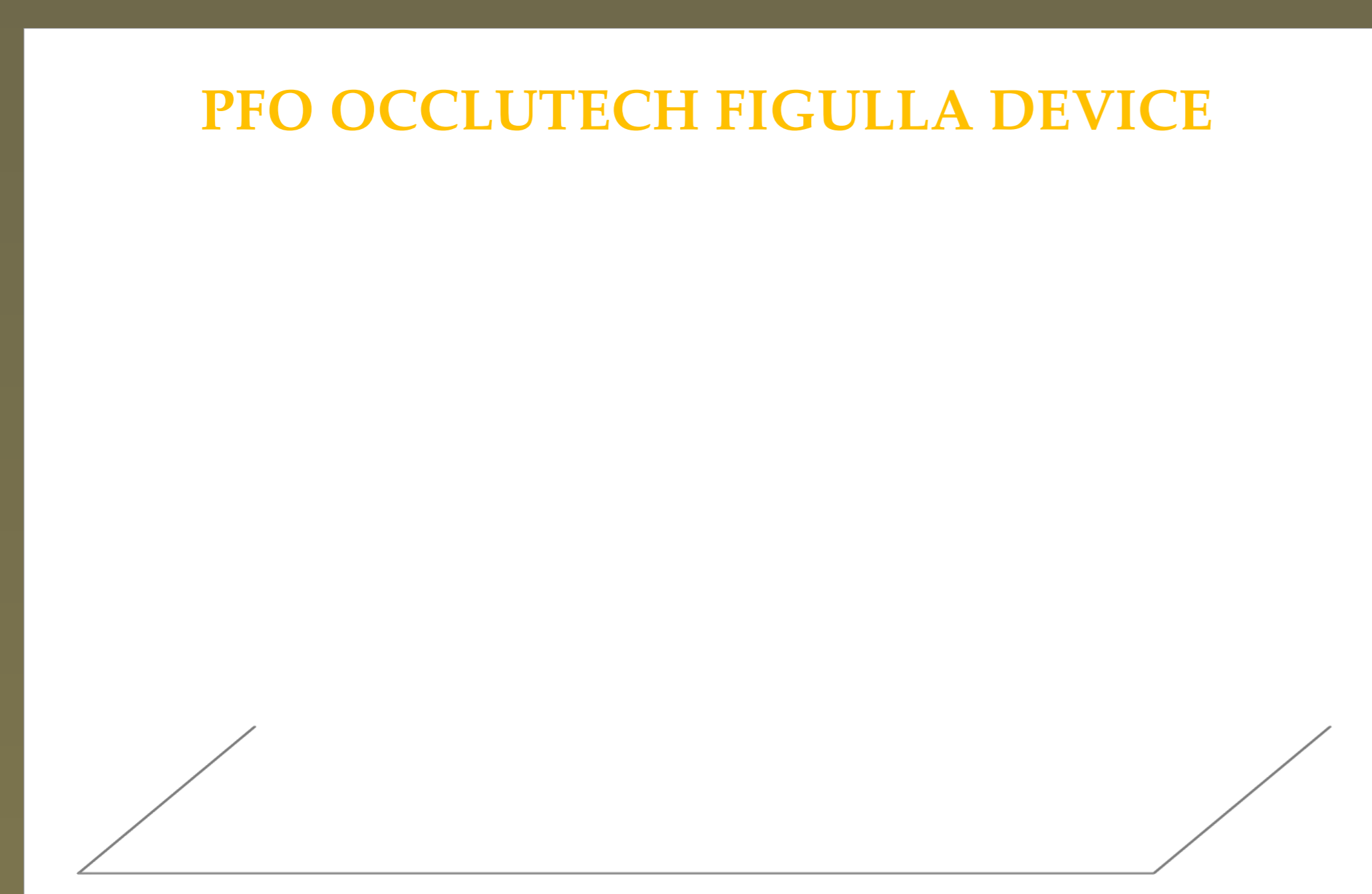
Objective To describe a single-centre experience with implantation of Occlutech in 62 PFO patients after cryptogenic stroke. .

Methods: All patients who underwent percutaneous PFO closure with Occlutech between March 2008 and February 2011 were included. These patients had TE ECHO and transcranial Doppler showing RA to LA shunt (spontaneously or after Valsalva maneuver) using saline agitated solution).




FLUOROSCOPIC AND TEE ASPECT OF RELEASED OCCLUTECH DEVICE

The procedure was done by mild sedation, TE ECHO and a single dose of prophylactic antibiotic in all of them. They stayed at the hospital 24 hours. ASA 3mg/kg/day was maintained for 6 months, TT ECHO and Transcranial Doppler were done: 1, 6 and 12 months after the intervention.



DOUBLE LAYER OCCLUTECH FIGULLA N 23/25 DEVICE



SINGLE LAYER OCCLUTECH FIGULLA DEVICE

Results: Successful device implantation was achieved in all cases. Transient atrial arrhythmia occurred in 2 cases. Types of devices: single-layer, double layer 23/25 and double layer 27/30 were used in 21, 23 and 18 patients respectively. Two patients had transient supraventricular tachycardia. Fever, headache and myalgia were observed in 8 patients, treated with symptomatic drugs. Residual shunt or recurrence of stroke were not observed in this follow up period .

Conclusions: In this study, Occlutech PFO occluder showed to be safe, easy to manipulate and effective for PFO closure.